

For closed-wedge varus distal femoral osteotomies

Tomofix Medial Distal Femur (MDF)

Surgical Technique

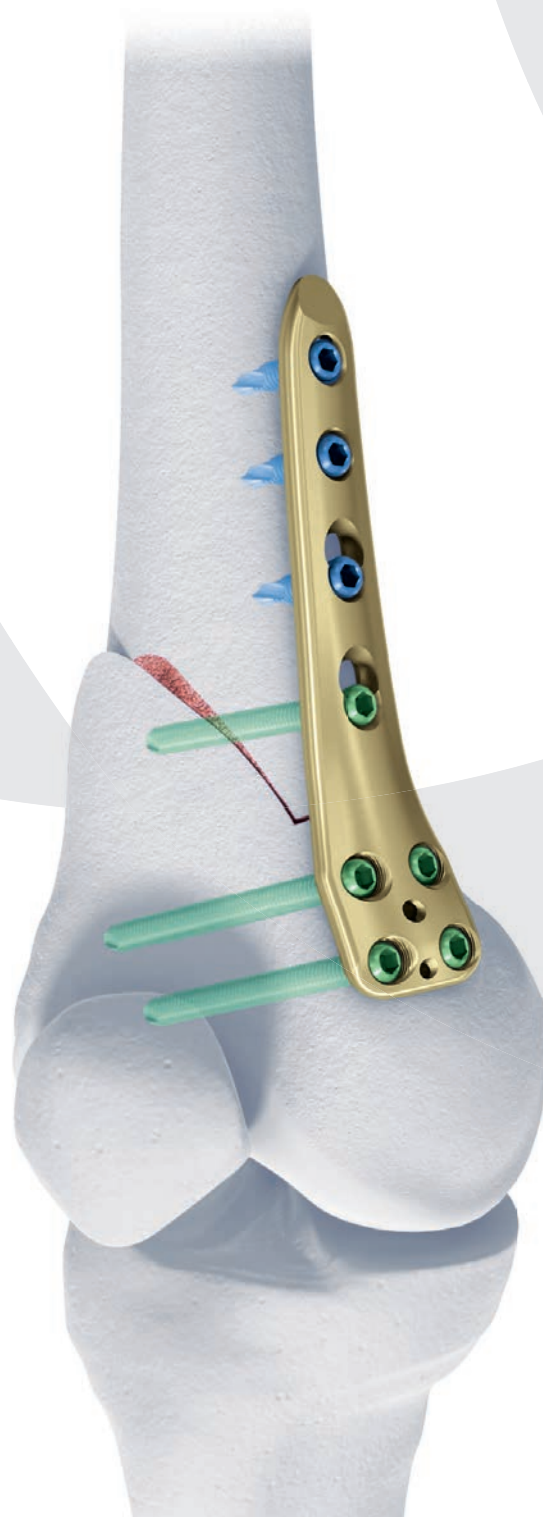


 Image intensifier control

This description alone does not provide sufficient background for direct use of DePuy Synthes products. Instruction by a surgeon experienced in handling these products is highly recommended.

Processing, Reprocessing, Care and Maintenance

For general guidelines, function control and dismantling of multi-part instruments, as well as processing guidelines for implants, please contact your local sales representative or refer to:

<http://emea.depuysynthes.com/hcp/reprocessing-care-maintenance>

For general information about reprocessing, care and maintenance of Synthes reusable devices, instrument trays and cases, as well as processing of Synthes non-sterile implants, please consult the Important Information leaflet (SE_023827) or refer to:

<http://emea.depuysynthes.com/hcp/reprocessing-care-maintenance>

Table of Contents

Introduction	TomoFix Medial Distal Femur (MDF)	2
	Additional Notes	4
	AO Principles	5
	Indications and Contraindications	6

Surgical Technique	Preparation and Approach	7
	Osteotomy	10
	Positioning and Fixation of the Plate	14
	Postoperative Treatment	23
	Implant Removal	24

Product Information	Implants	25
	Instruments	26
	Cases	31

Bibliography	32
---------------------	----

MRI Information	33
------------------------	----

TomoFix Medial Distal Femur (MDF). For closed-wedge varus distal femoral osteotomies.


Features and Benefits

Reduced prominence

Chamfer at the distal plate end

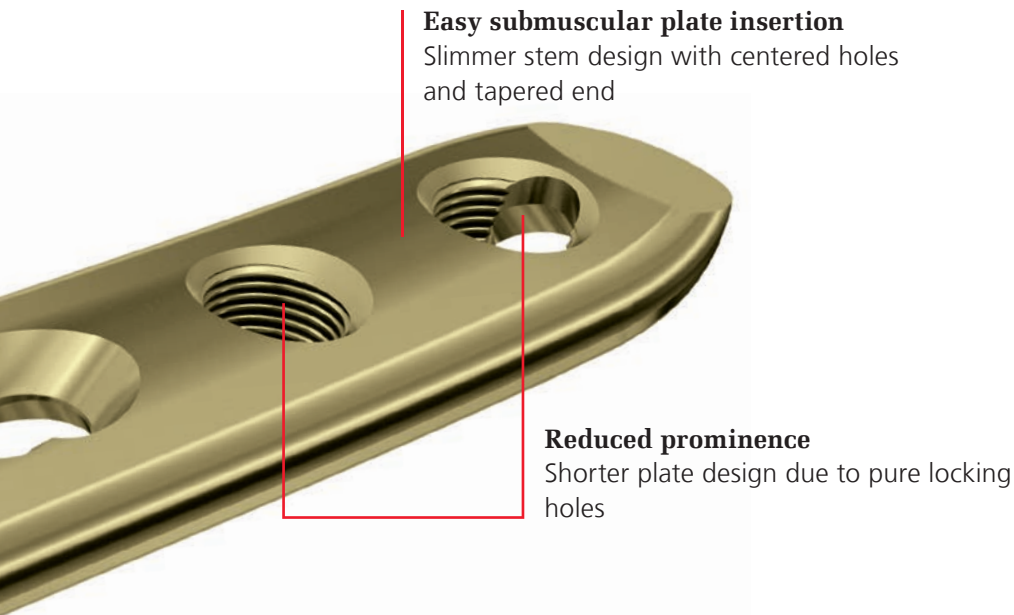
Anatomical fit

Twisted neck (stem in relation to head)

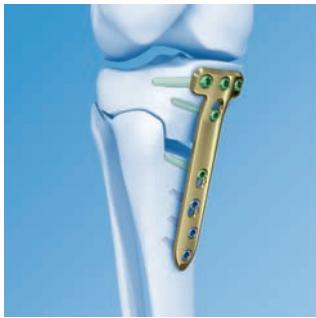

Improved screw direction

Curved plate positions screws centrally through the medullary canal

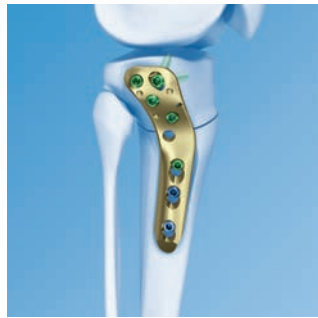


TomoFix Knee Osteotomy System



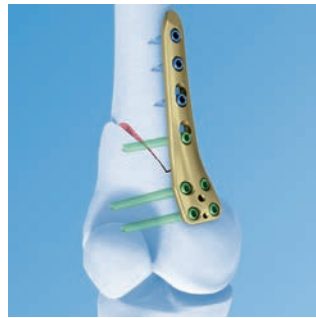TomoFix Tibial Head Plate medial, proximal

- For open and closed-wedge high tibial osteotomies
- Increased plate strength allows application of the preload technique
- Facilitates the support for stable bridging
- Available in standard and small stature versions



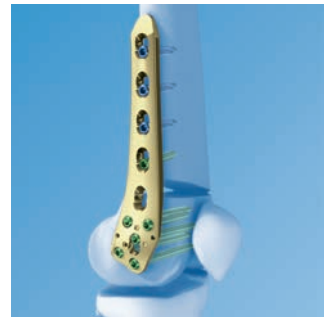
TomoFix Tibial Head Plate lateral, proximal

- For open and closed-wedge osteotomies
- Fixed-angle construct for stable fixation
- Available in right and left versions



TomoFix Femoral Plate medial, distal

- For closed-wedge osteotomies
- Fixed-angle construct for stable fixation
- Available in right and left versions



TomoFix Femoral Plate lateral, distal

- For open and closed-wedge osteotomies
- Fixed-angle construct for stable fixation
- Available in right and left versions

Additional Notes (read carefully before proceeding)

- **When manifest instability of the lateral bony bridge is identified intraoperatively, the use of an additional lateral implant is highly recommended.**

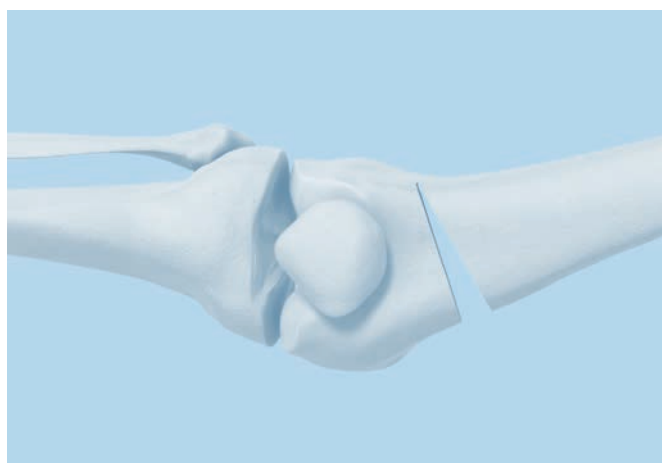

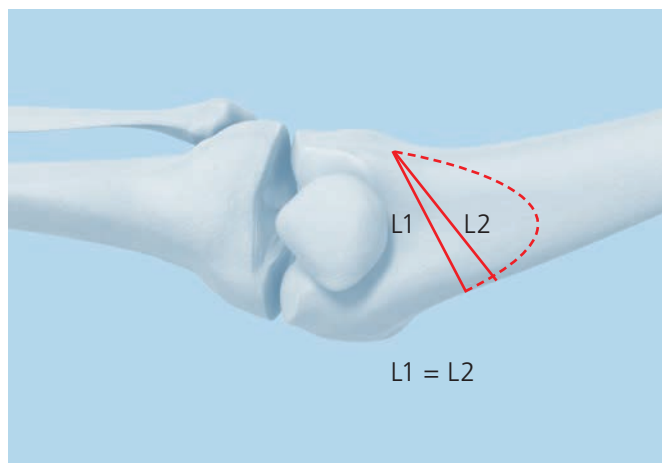
- An exact preoperative plan is crucial to the success of this procedure. It must be done on the weight bearing x-ray of the full leg in AP view, either on paper or at a digital workstation.
- If the osteotomy wedge removed is too large, this may result in instability of the construct.
- Direction and localization of the osteotomy are important for primary stability. To achieve a high level of stability, make sure that the transverse osteotomy
 - is **isosceles** ($L1 = L2$). This ensures full cortical contact after closing the osteotomy.
 - is **oblique**. This maximizes the contact surface.
 - runs **from the medial metaphyseal area into the lateral condyle** as blood supply and biomechanical circumstances are most suitable in this area.
- Always use sharp saw blades as the use of a blunt saw blade may lead to thermal necrosis of the bone and the surrounding soft tissue.

- **Note on biplanar osteotomy technique^{1,2}:**

The AO Knee Expert Group advises to use a biplanar osteotomy technique for closed-wedge varus osteotomies of the medial distal femur. In this technique two incomplete sawcuts in the frontal plane are combined with a sawcut in the sagittal plane to improve intraoperative stability, postoperative functional rehabilitation and shorten bone healing time and time to full weight bearing.

Alternative^{3,4}:

The closed wedge varus femur osteotomy may also be performed as a single plane osteotomy fixed with the Tomofix MDF plate.



AO Principles

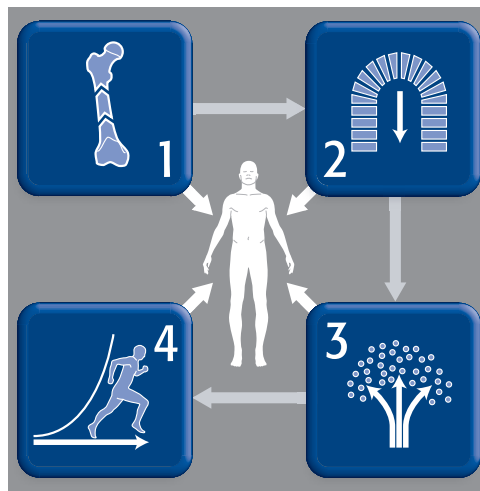
In 1958, the AO formulated four basic principles, which have become the guidelines for internal fixation^{1,2}.

Anatomic reduction

Fracture reduction and fixation to restore anatomical relationships.

Early, active mobilization

Early and safe mobilization and rehabilitation of the injured part and the patient as a whole.



Stable fixation

Fracture fixation providing absolute or relative stability, as required by the patient, the injury, and the personality of the fracture.

Preservation of blood supply

Preservation of the blood supply to soft tissues and bone by gentle reduction techniques and careful handling.

¹ Müller ME, Allgöwer M, Schneider R, Willenegger H. Manual of Internal Fixation. 3rd ed. Berlin, Heidelberg, New York: Springer. 1991.

² Rüedi TP, Buckley RE, Moran CG. AO Principles of Fracture Management. 2nd ed. Stuttgart, New York: Thieme. 2007.

Indications and Contraindications

Indications

Closed-wedge osteotomies of the medial distal femur for the treatment of:

- Unicompartmental lateral gonarthrosis with valgus malalignment of the distal femur
- Idiopathic or posttraumatic valgus deformity of the distal femur
- Additional fixation for complex distal femoral fractures

Contraindication

- Inflammatory arthritis

Note: When manifest instability of the lateral bony bridge is identified intraoperatively, the use of an additional lateral implant is highly recommended.

Preparation and Approach

1. Prepare the implant

03.120.068	TomoFix Guiding Block, for right TomoFix Femoral Plate, medial, distal
or	
03.120.069	TomoFix Guiding Block, for left TomoFix Femoral Plate, medial, distal
323.042	LCP Drill Sleeve 5.0, for Drill Bits Ø 4.3 mm

To allow uniform orientation the four combination holes in the proximal stem are numbered 1–4 and the four plate holes in the distal segment are labeled A–D. Ensure that the correct implant (right/left) is selected.

Use the guiding block as a positioning guide to align the drill sleeves on the distal part of the TomoFix Femoral Plate (MDF).

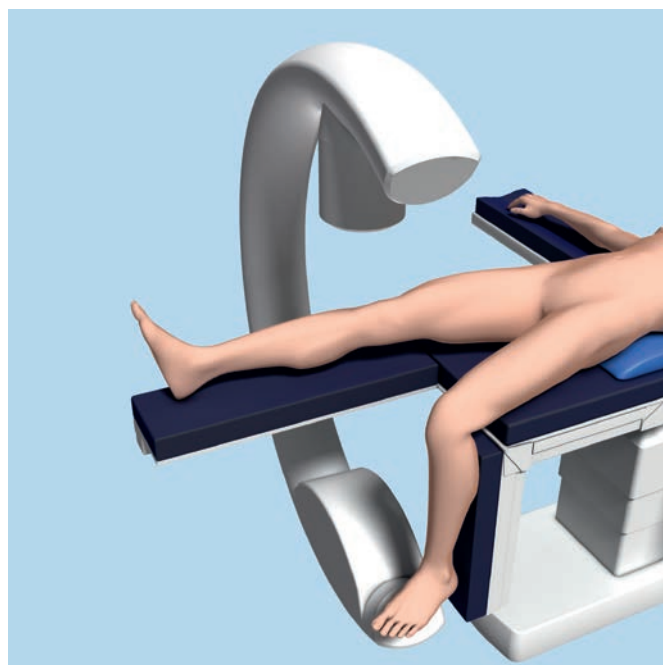
Insert the drill sleeves exactly along the guiding block. First screw the drill sleeve into hole A, then proceed to screw the drill sleeves into the three remaining holes B–D.

Remove the guiding block.



2. Position the patient

Surgery is performed with the patient in a supine position. Position the patient so that the hip, knee and ankle joint can be visualized with the image intensifier. Lower the contralateral leg at the hip joint to facilitate access to the medial distal femur. The sterile draping also exposes the iliac crest so that the leg axis can be checked intra-operatively. A sterile tourniquet can be used, but is not mandatory.



3. Approach

With the knee joint in extension, make an anteromedial longitudinal incision, starting 10 cm above the patella and ending in the upper third of the patella. This incision has the advantage that it can be used again for any subsequent surgery (i.e. endoprosthesis).

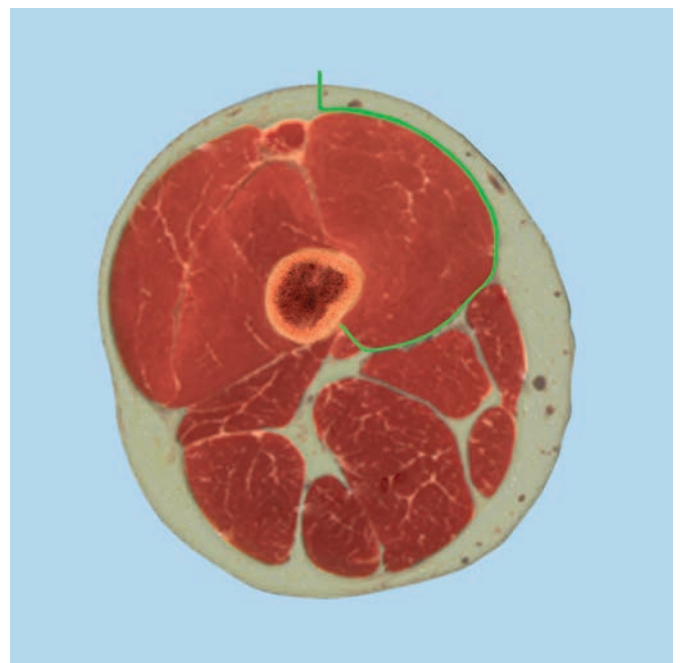
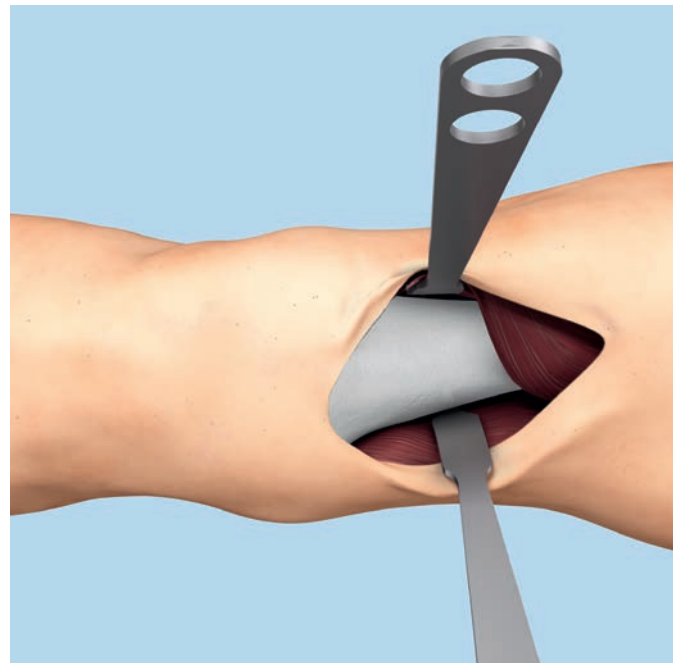
Incise the subcutaneous tissue and dissect the fascia from the vastus medialis muscle. Elevate the muscle from the intermuscular septum and dissect as far as necessary for plate positioning on the femur shaft.

Position a retractor on the lateral side, over the soft tissues covering the ventral part of the femur. In the bipolar osteotomy technique visualization of the ventral part of the femur is not necessary. Incise the distal insertion of the vastus medialis muscle in order to facilitate mobilization of the muscle. Now expose the intermuscular septum near the condyles. Incise the periosteum just ventral to the septum. Use a curved elevator to separate the soft tissue from the back of the distal femur so that a wide, blunt-tipped Hohmann retractor can be inserted behind the femoral shaft.

Precaution: An osteotomy of the distal femur may be carried out only if the neurovascular structures are protected with a blunt retractor. Otherwise there is a high risk of injuring these vital structures.

Use a Hohmann retractor to expose the anteromedial aspect of the supracondylar region of the femur leaving the soft tissue covering the bone intact. Expose the femoral shaft proximally so that the TomoFix Femoral Plate (MDF) can be positioned safely.

If the plate is used for fracture fixation proceed on page 14 "Positioning and Fixation of the Plate".



Osteotomy

1. Determine the position of the osteotomy

Instrument

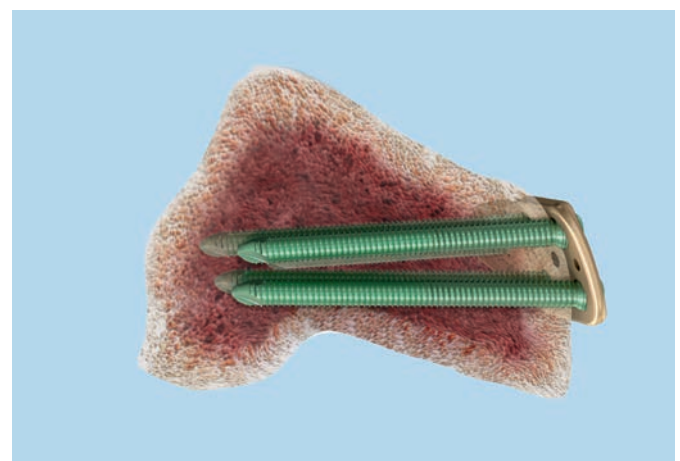
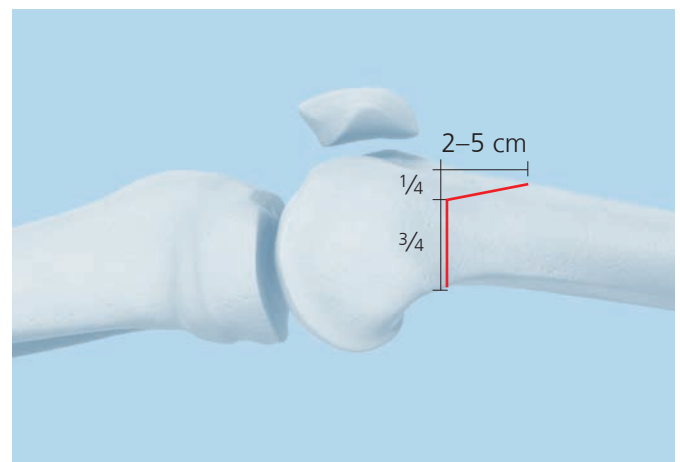
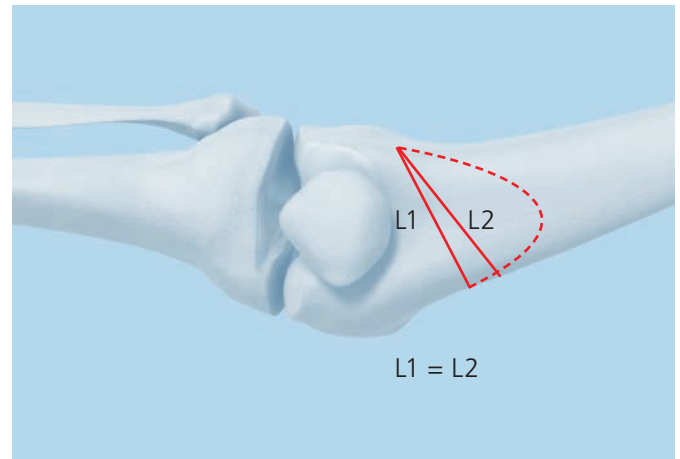
292.210 Kirschner Wire \varnothing 2.0 mm with trocar tip, length 280 mm, Stainless Steel

The position of the osteotomy is best determined by placing the TomoFix Femoral Plate (MDF) directly on the anteromedial distal femur. It is not necessary to achieve a form fit due to the angular stability. However, it is important to ensure that the distal screws do not penetrate the condyles dorsally.

Plan a biplanar osteotomy with the transverse plane perpendicular to the dorsal and the medial cortex. The transverse osteotomy cuts should pass through $\frac{3}{4}$ of the bone leaving the ventral $\frac{1}{4}$ intact, and end 5–10 mm before the lateral cortical bone, leaving a lateral hinge. The coronal cut must ascend anteriorly at 90° – 110° and should exit the anterior cortex after 2–5 cm. The transverse osteotomy should be located under the solid region of the plate to allow screws A–D to be positioned distal of the osteotomy.

Precaution: Direction and localization of the osteotomy are important for primary stability. To achieve a high level of stability, make sure that the transverse osteotomy

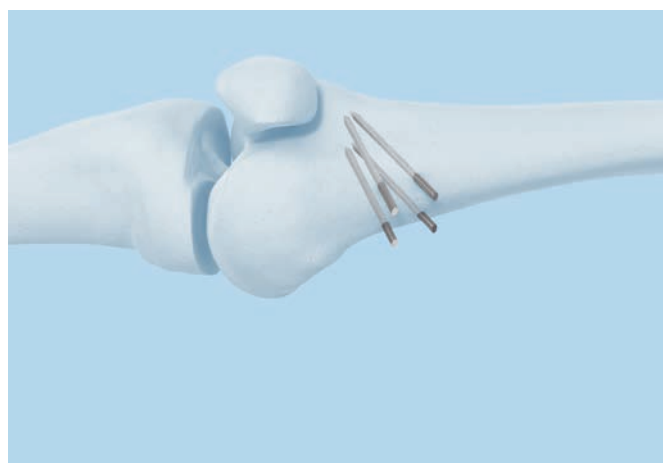
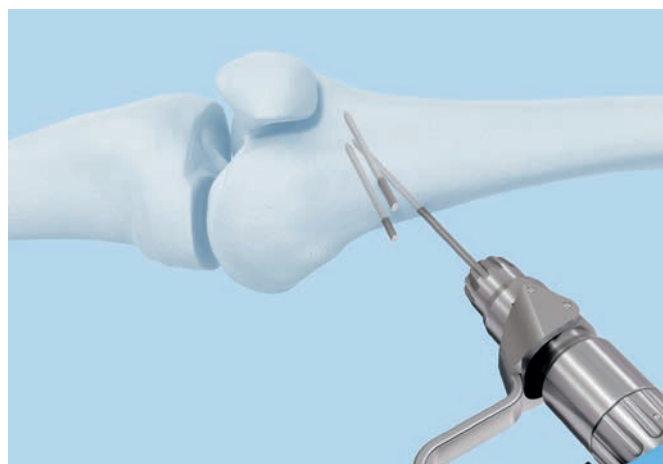
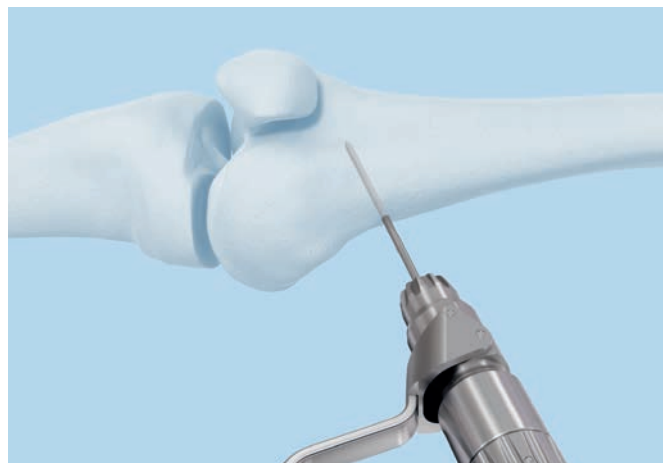
- is **isosceles** ($L1 = L2$). This ensures full cortical contact after closing the osteotomy.
- is **oblique**. This maximizes the contact surface.
- runs **from the medial metaphyseal area into the lateral condyle** as blood supply and biomechanical circumstances are most suitable in this area.



- ① Using the image intensifier, choose the hinge point of the osteotomy just proximal to the upper margin of the lateral femur condyle 5–10 mm from the lateral cortex. Insert two Kirschner wires aimed to coincide at the hinge point. The distance between the Kirschner wires at the entry point is according to the preoperative planning which is checked using a ruler. Insert two other Kirschner wires parallel to the first ones.

The resulting wedge should be isosceles in order to ensure that the medial cortices will align after the osteotomy is closed.

Note: In order to monitor the rotation when closing the osteotomy after removing the wedge mark the bone proximal and distal of the osteotomy with electrocautery or Kirschner wires.



2. Osteotomy

Instruments

519.114	Saw Blade 116/95 × 19 × 21.25/1.13 mm for Oscillating Saw with AO/ASIF Coupling
519.106	Saw Blade 90/69 × 1 × 1.0/0.8 mm, for Oscillating Saw with AO/ASIF Coupling

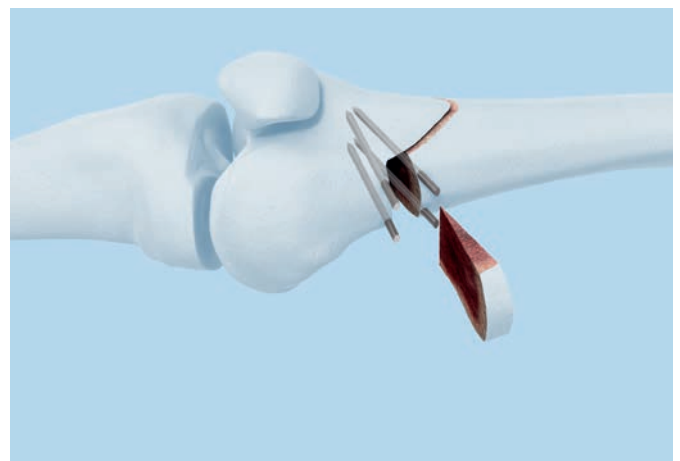

Perform the transverse osteotomy cuts in the dorsal $\frac{3}{4}$ of the bone parallel to the inserted Kirschner wires. The wires will then act as a guide for the saw. Perform the osteotomies with a an oscillating saw, protecting the soft tissues dorsally with a Hohmann retractor and constantly cooling the saw blade.

Perform the ascending osteotomy cut in the ventral $\frac{1}{4}$ of the bone with a thinner saw blade protecting the soft tissue with the Langenbeck soft tissue retractor and constantly cooling the saw blade.

Remove the wedge and check that any residual bone fragments have been removed from the osteotomy before closing. If the bone is very hard, weaken the lateral cortical bone with a 2.5 mm drill bit or Kirschner wire.

Precaution: Proceed cautiously around the neurovascular structures. Saw in a slow and controlled manner to prevent the blade from deviating into the back of the knee. Ensure the retractor always follows the osteotomy lines while cutting. In order to avoid potential heat necrosis during sawing procedure:

- * Continuously irrigate while sawing
- * Never use a blunt saw blade



3. Close osteotomy

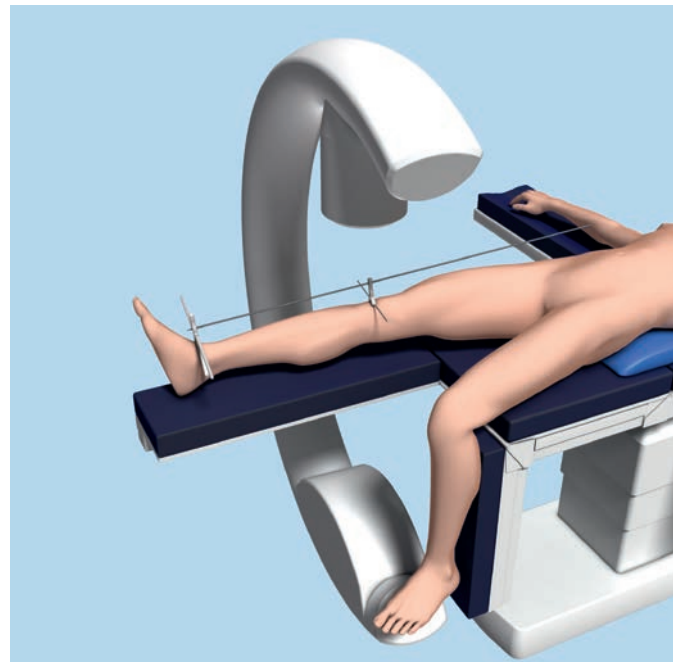
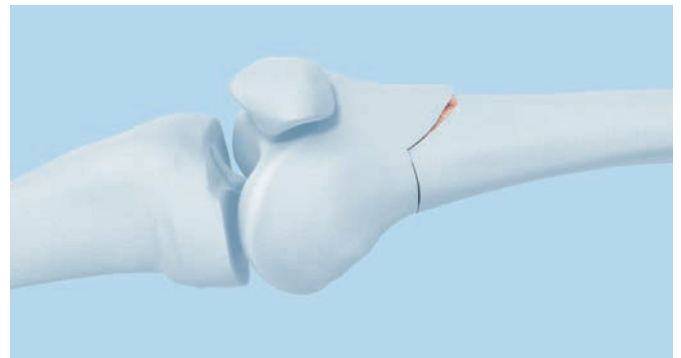
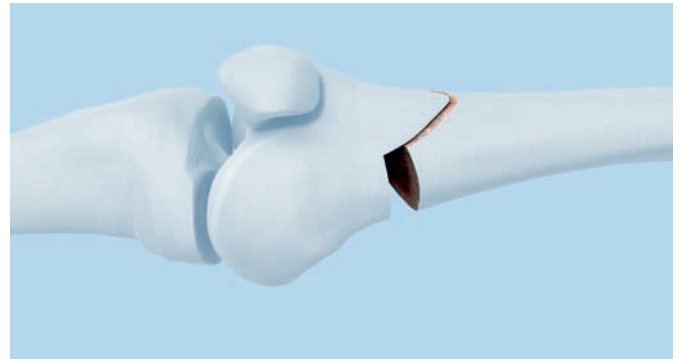
Instruments

03.108.030	Alignment Rod
03.108.031	Stand, large, for Alignment Rod, with handles
03.108.032	Stand, small, for Alignment Rod

Close the osteotomy carefully by applying continuous pressure to the lateral lower limb while stabilizing the knee joint region. This may take several minutes.

The osteotomy gap can then either be held closed by manual compression or with two crossed Kirschner wires, considering the later plate position.

- ① Check the corrected mechanical axis with the image intensifier. Position the alignment rod between the center of the femoral head and the center of the ankle joint. The projected axis line passes either centrally or medially through the center of the knee joint, depending on the preoperative planning.



Positioning and Fixation of the Plate

1. Position the implant

Instruments

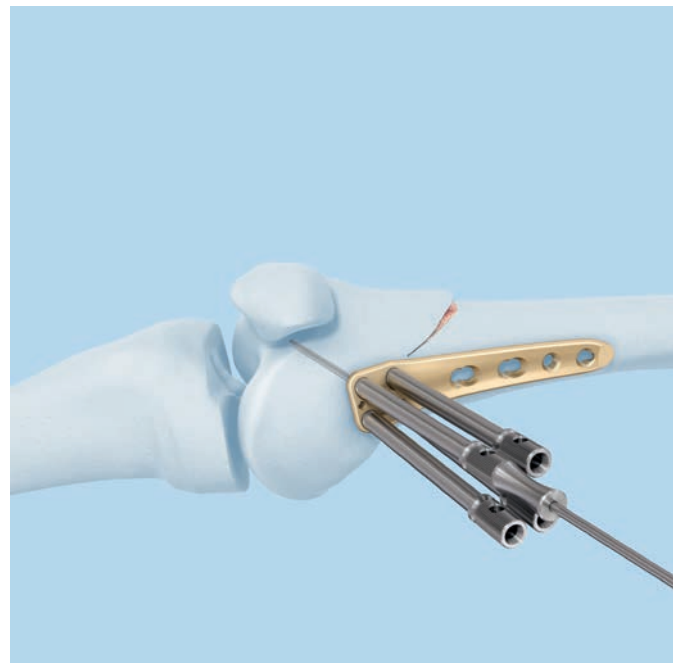
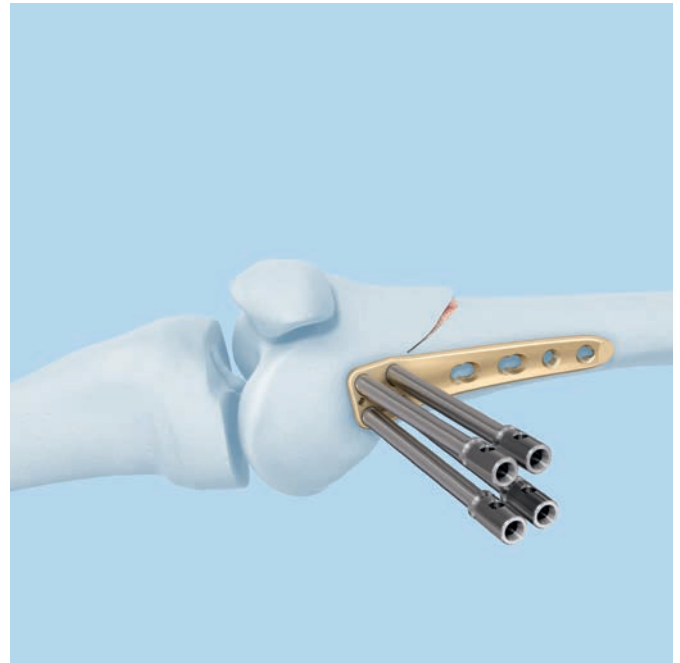
323.044	Centering Sleeve for Kirschner Wire Ø 2.0 mm, length 110 mm, for No. 323.042
292.210	Kirschner Wire Ø 2.0 mm with trocar tip, length 280 mm, Stainless Steel

Position the TomoFix Femoral Plate (MDF) anteromedially on the distal femur.

Precaution: Use the four distal pre-mounted drill sleeves as described on page 7, so that the solid plate segment bridges the osteotomy and the implant stem is aligned parallel to the femoral shaft.

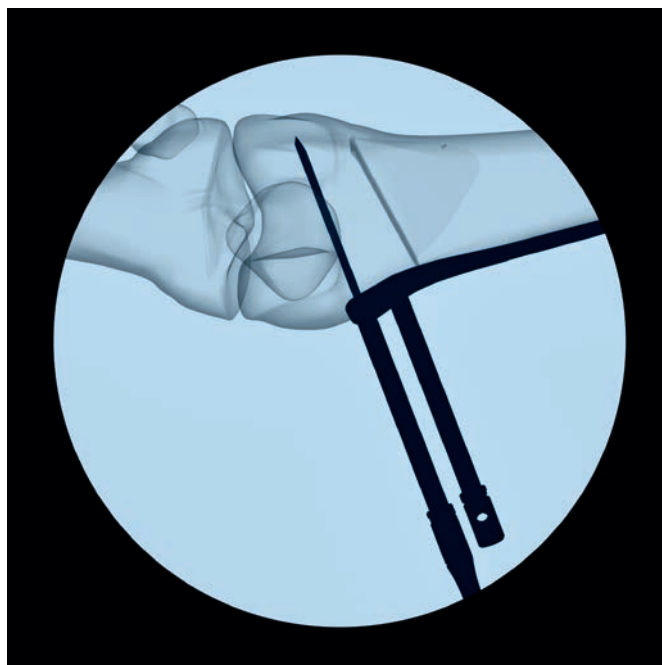
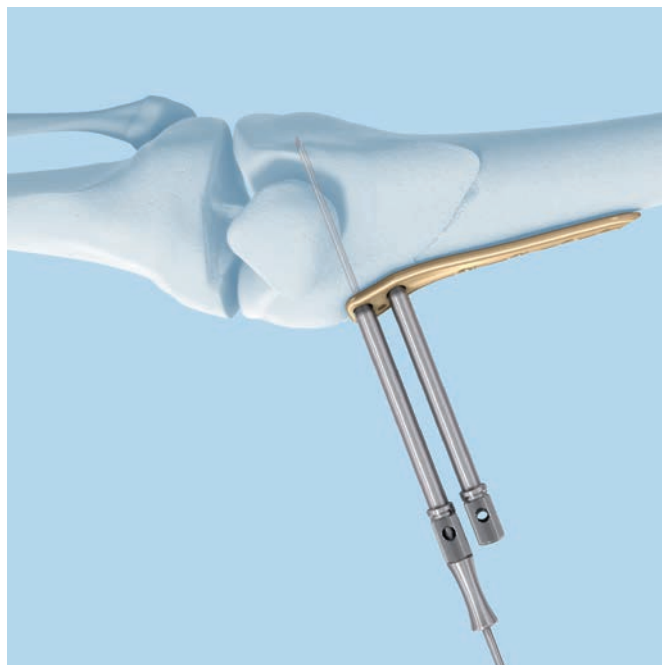
Temporarily secure the plate through the drill sleeve.

Precaution: Use a centering sleeve and a Kirschner Wire in plate hole A.



- **Precaution:** Check plate position and trajectory of the Kirschner wire under the image intensifier. The Kirschner wire must not exit the condyles posteriorly. Check by palpation and if necessary modify the plate position or sagittal tilt.

- A second Kirschner wire may be inserted in plate hole 3 to maintain the alignment of the plate relative to the femur shaft during distal plate fixation.



2. Distal fixation of the TomoFix Femoral Plate

Instruments

310.430	LCP Drill Bit \varnothing 4.3 mm with Stop, length 221 mm, 2-flute, for Quick Coupling
319.100	Depth Gauge for Screws \varnothing 4.5 to 6.5 mm, measuring range up to 110 mm
397.705	Handle for Torque Limiter Nos. 511.770 and 511.771
511.771	Torque Limiter, 4 Nm, for Compact Air Drive and Power Drive
314.150	Screwdriver Shaft, hexagonal, large, \varnothing 3.5 mm

Drill screw holes.

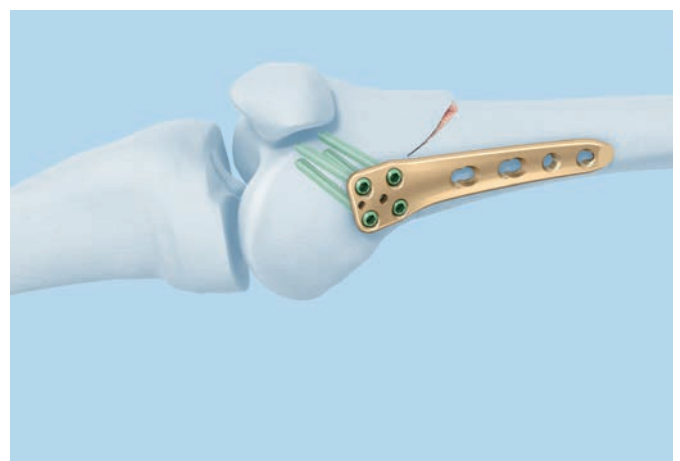
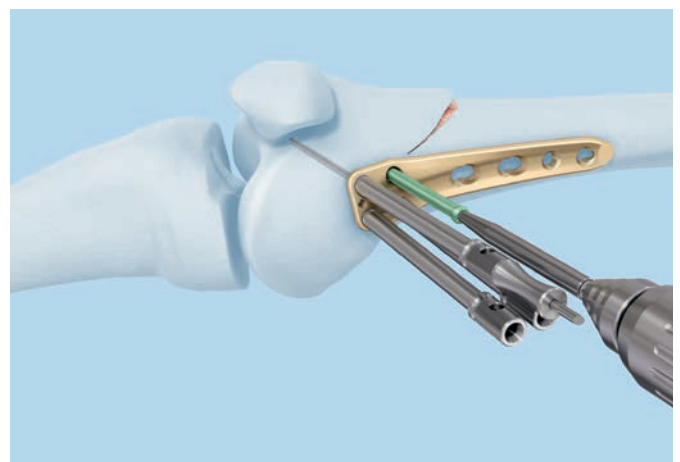
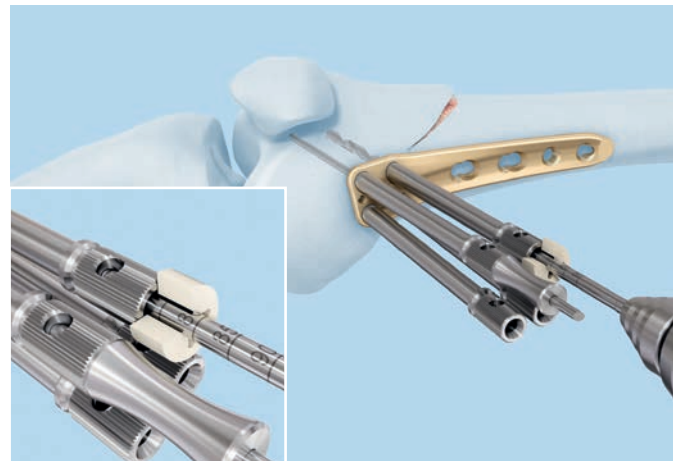
Precaution: Use the drill sleeves for self-tapping locking screws and the LCP drill bit \varnothing 4.3 mm.

Determine the screw length either by reading the drilled depth from the laser mark on the drill bit or with the depth gauge after removing the drill sleeve. The selected screws should be as long as possible without protruding through the lateral cortical bone.

Insert the screws using a power tool, but do not fully tighten. Insert screws in holes B, C and D. Remove the Kirschner wire from hole A and replace it with a locking screw. Using the image intensifier, exert special care to ensure that the screws do not penetrate the intercondylar notch.

Finally, lock the screws manually using the torque limiter. After one click, the optimum torque is reached.

If the plate is used for fracture fixation proceed on page 19 "Proximal fixation of the TomoFix Femoral Plate".



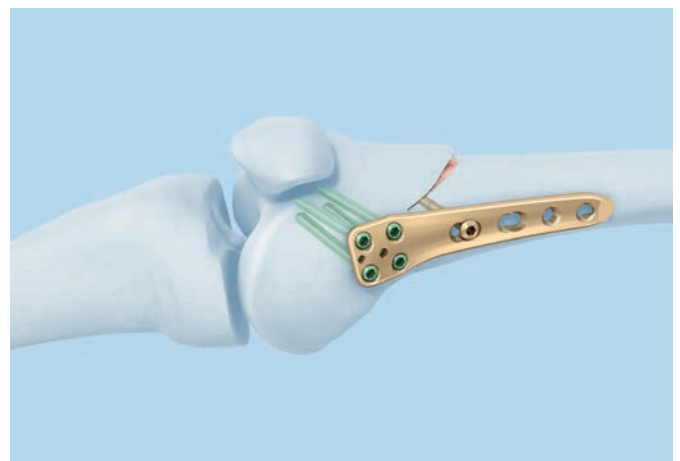
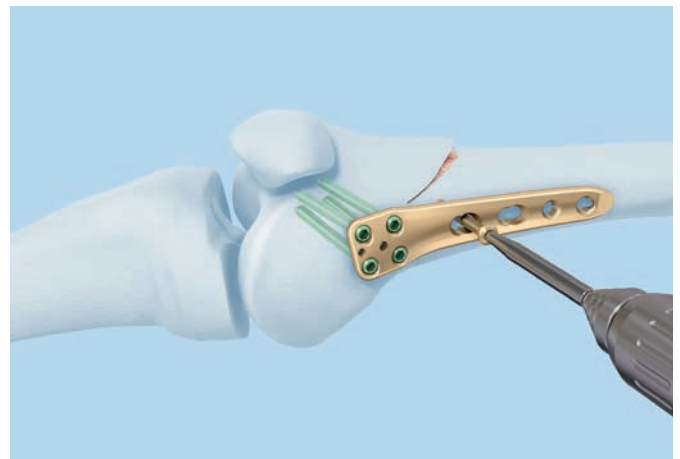
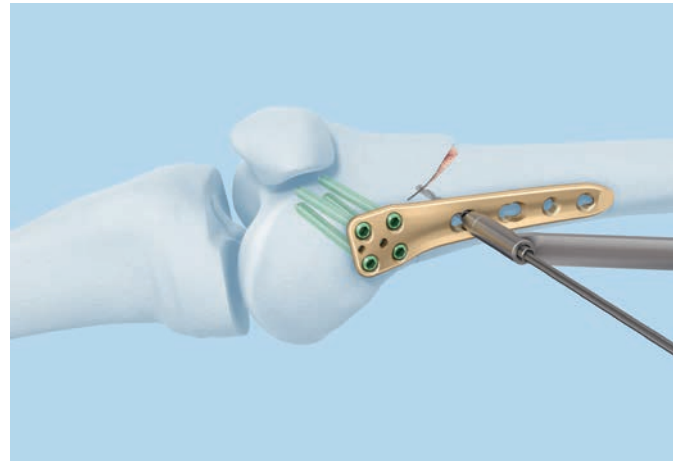
3. Temporary compression of the osteotomy gap

Instruments

323.500	LCP Universal Drill Guide 4.5/5.0
315.310	Drill Bit Ø 3.2 mm, length 145/120 mm, 3-flute, for Quick Coupling
319.100	Depth Gauge for Screws Ø 4.5 to 6.5 mm, measuring range up to 110 mm
397.705	Handle for Torque Limiter Nos. 511.770 and 511.771
511.771	Torque Limiter, 4 Nm, for Compact Air Drive and Power Drive
314.150	Screwdriver Shaft, hexagonal, large, Ø 3.5 mm

The osteotomy gap can be compressed by eccentrically applying a self-tapping 4.5 mm cortex screw proximal to the osteotomy in the dynamic part of combination hole 1.

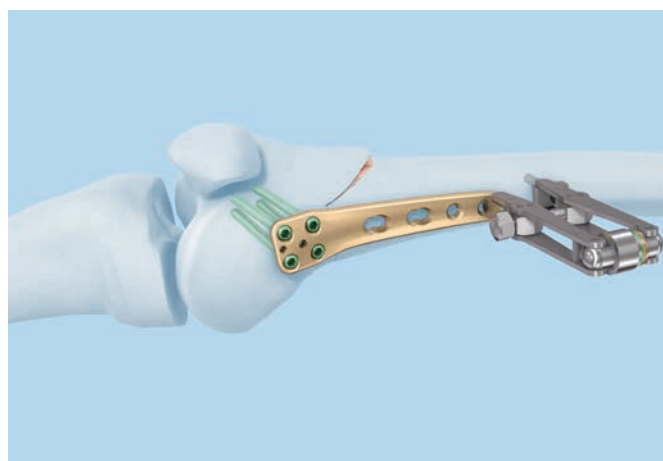
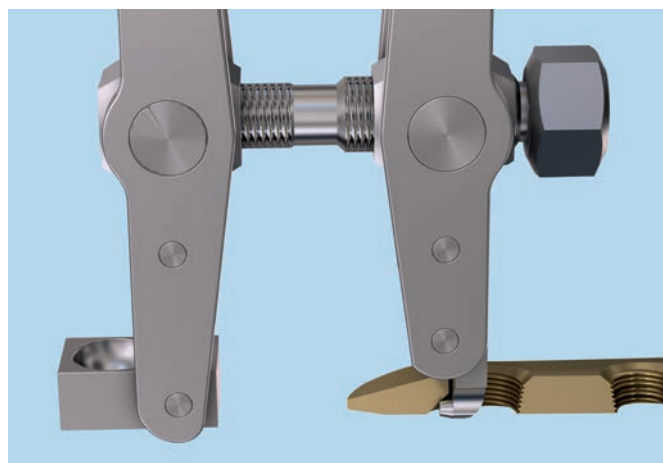
The screw should be inserted perpendicular to the plate surface to achieve good interfragmentary compression. This is particularly important if the lateral femoral cortical bone fractured during closure of the osteotomy.



Alternative instrument

321.120 Tension Device, articulated, span 20 mm

Alternatively, the articulated tension device can be used to create compression in the dynamic section of plate hole 4. This requires additional proximal soft tissue dissection.

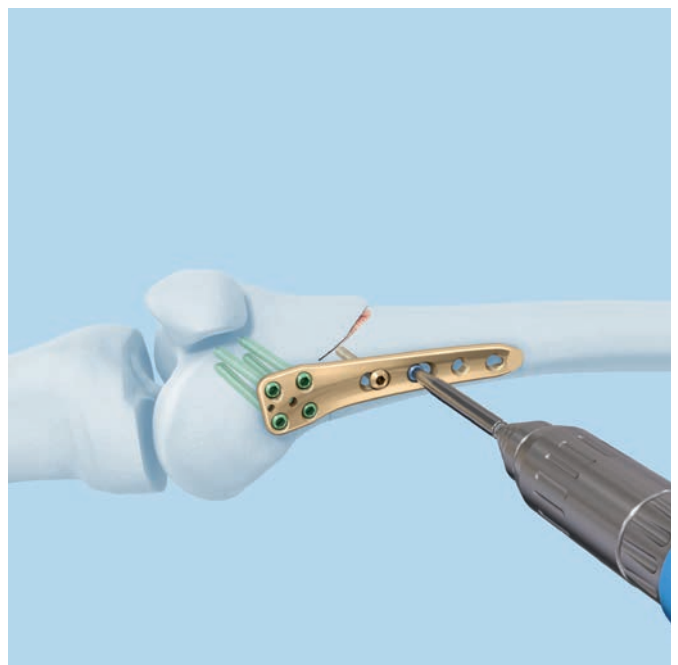
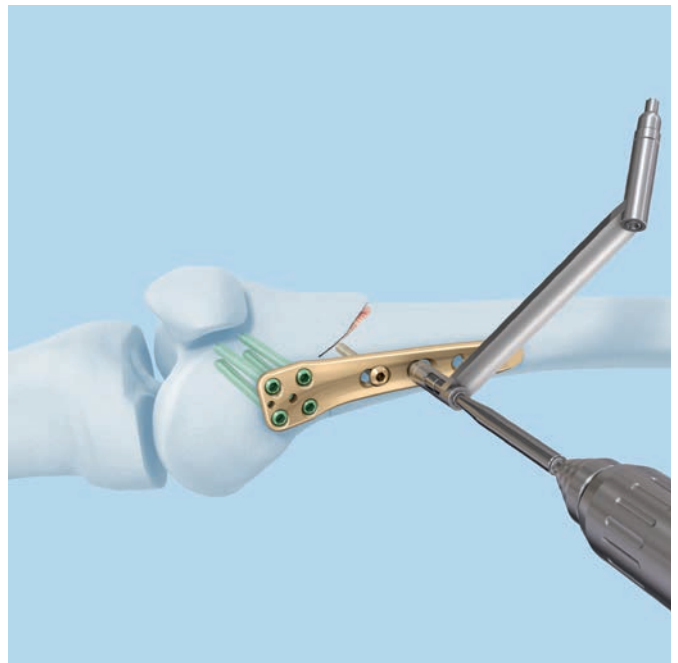


4. Proximal fixation of the TomoFix Femoral Plate

Instruments

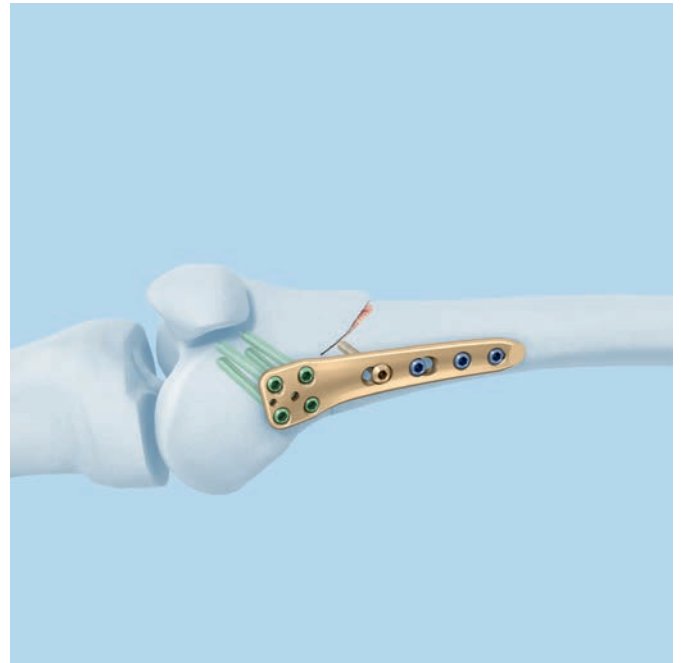
323.500	LCP Universal Drill Guide 4.5/5.0
315.310	Drill Bit Ø 3.2 mm, length 145/120 mm, 3-flute, for Quick Coupling
397.705	Handle for Torque Limiter Nos. 511.770 and 511.771
511.771	Torque Limiter, 4 Nm, for Compact Air Drive and Power Drive
314.150	Screwdriver Shaft, hexagonal, large, Ø 3.5 mm

Use an LCP universal drill guide to mark the medial femoral cortical bone with the short drill bit. Screw in the locking screw using a power tool and tighten it using the technique described on page 16.



Insert monocortical, self-tapping locking screws into plate holes 2–4 of the implant stem from distal to proximal.

Note: In cases requiring increased stability such as compromised bone quality or obese patients, the use of bicortical screws may be indicated.



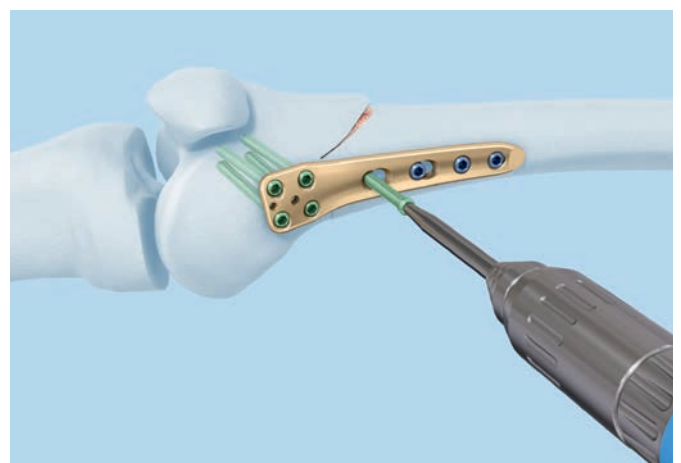
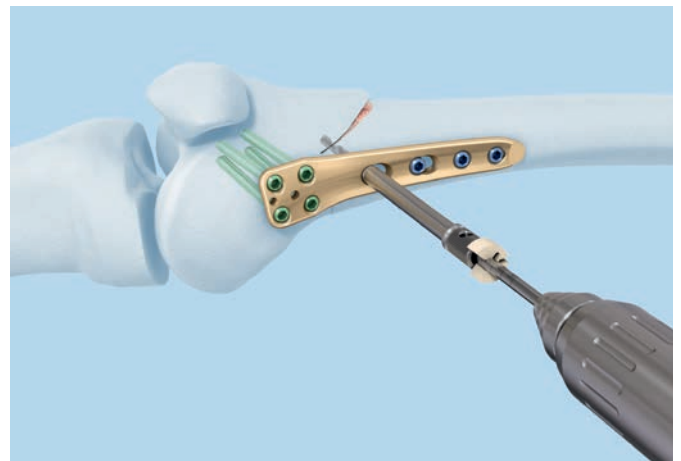
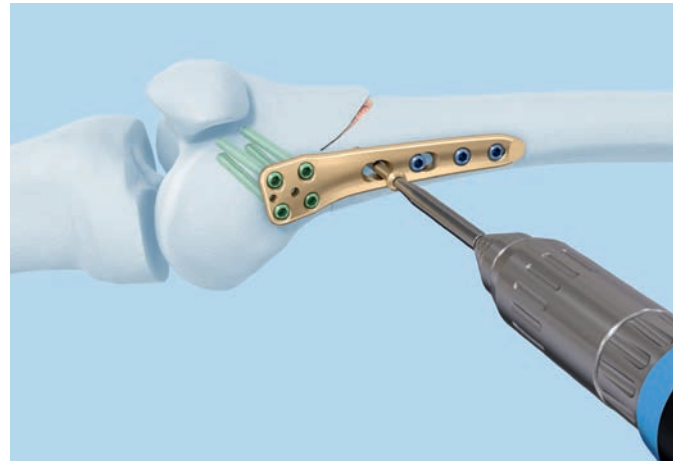
5. Replace the cortex screw

Instruments

323.042	LCP Drill Sleeve 5.0, for Drill Bits Ø 4.3 mm
310.430	LCP Drill Bit Ø 4.3 mm with Stop, length 221 mm, 2 flute, for Quick Coupling
319.100	Depth Gauge for Screws Ø 4.5 to 6.5 mm, measuring range up to 110 mm
397.705	Handle for Torque Limiter Nos. 511.770 and 511.771
511.771	Torque Limiter, 4 Nm, for Compact Air Drive and Power Drive
314.150	Screwdriver Shaft, hexagonal, large, Ø 3.5 mm

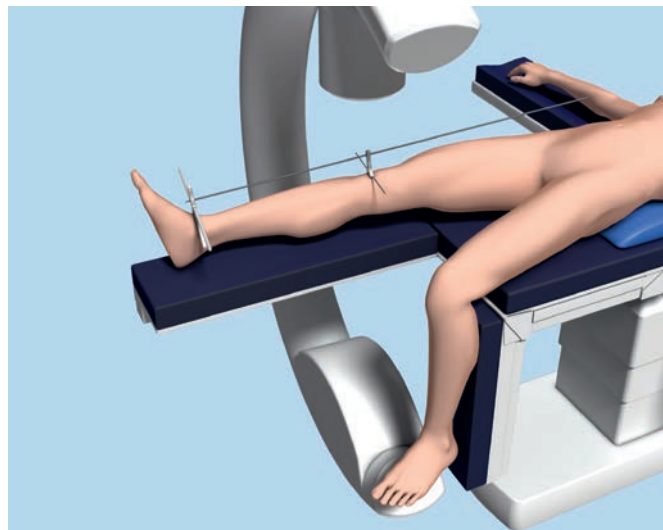
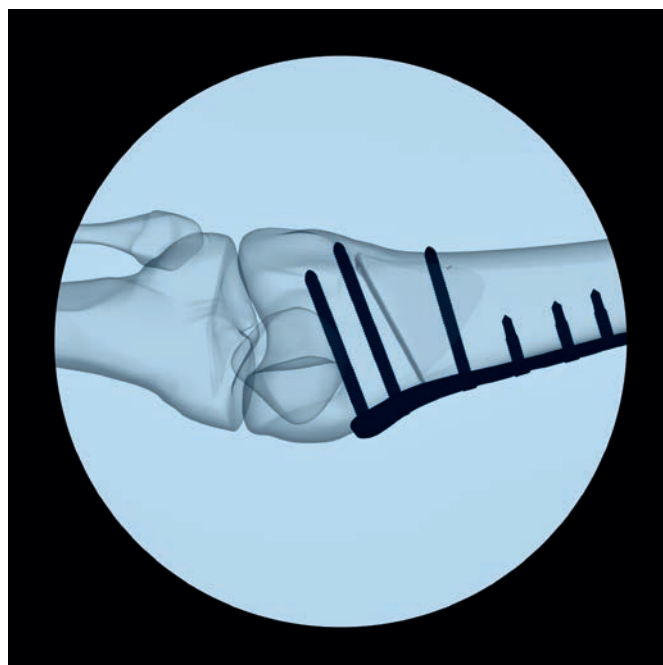
Remove the cortex screw from hole 1 and replace it with a bicortical, self-tapping locking screw. Screw the drill sleeve exactly into the threaded part of the combi-hole and drill the hole with the LCP drill bit Ø 4.3 mm. Determine the screw length and insert the screw as described on page 16.

Note: In the event of a rotational osteotomy or breakage of the lateral hinge, the surgeon should consider adding a lateral implant.



6. Radiological control

- Check the result of the correction and the position of the implant using the image intensifier.



7. Wound closure

Re-insert the partially released distal insertion of the vastus medialis muscle on the patella. Close the wound in layers.

Postoperative Treatment

Normal rehabilitation protocol

Early functional postoperative treatment from the first postoperative day, partial load weight bearing of 15–20 kg for 6 weeks postoperatively, manual lymphatic drainage, cryotherapy and electrotherapy if necessary. The range of motion is not limited, an orthosis is not necessary, abduction and adduction against resistance and torsion in the lower leg should be avoided for the first 6 weeks. Increased weight bearing is allowed from the 7th week postoperatively depending on the radiological healing of the osteotomy site.

Early full weight bearing protocol

Immediate full weight bearing upon pain may be considered in patients that can be trusted to be compliant to instructions. To limit torsion forces over the osteotomy during immediate full weight bearing a hinged knee brace is advised during the first 6 weeks.⁵

Radiographic control after 2 days, 6 and 12 weeks and 12 months.

Note: The described rehabilitation protocols are examples only. They must be individually assessed for each patient.

Implant Removal

Generally, the TomoFix Femoral Plate (MDF) should not be removed earlier than 12 months after surgery. To remove the plate, first loosen all screws manually and then remove them using power tools.

Implants

The TomoFix Femoral Plate (MDF) is designed according to the principles of the Locking Compression Plate (LCP). In the distal section there are 4 threaded holes, the directions of which are adapted to the anatomy of the supracondylar femur. There are 2 combi-holes and 2 locking holes in the proximal section. Right and left versions allow for accurate positioning of the antero-medial section of the distal femur and secure anchorage of the locking screws in the femoral condyles.

04.120.550 TomoFix Femoral Plate, medial, distal, right, 4 holes, Pure Titanium, sterile

For closed-wedge osteotomies of the right medial distal femur



04.120.551 TomoFix Femoral Plate, medial, distal, left, 4 holes, Pure Titanium, sterile

For closed-wedge osteotomies of the left medial distal femur



413.314–
413.390 Locking Screws Ø 5.0 mm, self-tapping, Titanium Alloy (TAN)





413.426 Locking Screw Ø 5.0 mm, self-drilling, length 26 mm, Titanium Alloy (TAN)



414.814–
414.490 Cortex screw Ø 4.5 mm, self-tapping, Pure Titanium



Instruments

292.210	Kirschner Wire \varnothing 2.0 mm with trocar tip, length 280 mm, Stainless Steel	
310.290	Drill Bit \varnothing 3.2 mm, length 195/170 mm, 2-flute, for Quick Coupling	
310.430	LCP Drill Bit \varnothing 4.3 mm with Stop, length 221 mm, 2-flute, for Quick Coupling	
311.460	Tap for Cortex Screws \varnothing 4.5 mm, length 125/70 mm	
314.119	Screwdriver Shaft Stardrive 4.5/5.0, T25, self-holding, for AO/ASIF Quick Coupling	
314.150	Screwdriver Shaft, hexagonal, large, \varnothing 3.5 mm	
319.100	Depth Gauge for Screws \varnothing 4.5 to 6.5 mm, measuring range up to 110 mm	

323.042 LCP Drill Sleeve 5.0, for Drill Bits
Ø 4.3 mm



323.044 Centering Sleeve for Kirschner Wire
Ø 2.0 mm, length 110 mm,
for No. 323.042



323.460 Universal Drill Guide 4.5/3.2, for neutral
and load position



323.500 LCP Universal Drill Guide 4.5/5.0



397.705 Handle for Torque Limiter Nos. 511.770
and 511.771



397.706 Handle for Torque Limiter No. 511.774



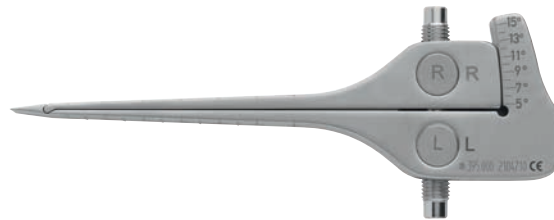511.771 Torque Limiter, 4 Nm, for Compact Air
Drive and Power Drive



511.774 Torque Limiter, 4 Nm, for AO/ASIF Quick Coupling for Reamers



395.000 TomoFix Bone Spreader



395.001 TomoFix Osteotomy Gap Measuring Device, Stainless Steel



397.992 TomoFix Osteotomy Chisel, width 10 mm



397.993 TomoFix Osteotomy Chisel, width 15 mm



397.994 TomoFix Osteotomy Chisel, width 20 mm



397.995 TomoFix Osteotomy Chisel, width 25 mm



399.097 Bone Spreader, soft lock, width 8 mm,
length 220 mm



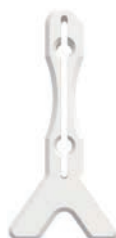03.108.030 Alignment Rod



03.108.031 Stand, large, for Alignment Rod,
with handles



03.108.032 Stand, small, for Alignment Rod



03.120.068 TomoFix Guiding Block, for right
TomoFix Femoral Plate, medial, distal




03.120.069 TomoFix Guiding Block, for left TomoFix
Femoral Plate, medial, distal




Cases

-
- 01.120.070 Instruments for TomoFix, in Modular Tray, Vario Case System
01.120.071 Implants for TomoFix, in Modular Screw Rack, Vario Case System

-
- 68.120.070 Modular Tray TomoFix Instrument Set, size 1/1, without Contents, Vario Case System



-
- 68.120.474 Modular Tray for LCP Instruments 4.5/5.0, size 1/2, without Contents, Vario Case System



-
- 68.120.071 Module for Screws, for TomoFix, for Frame, size 1/4
68.000.131 Auxiliary Module, size 1/2, height 28 mm, for Screw Rack, size 1/2
68.000.111 Screw Rack, size 1/2, height 77 mm



-
- 68.000.113 Screw Rack, size 1/2, with Drawer, length 100 mm, for Vario Case, height 88 mm

Bibliography

- ¹ Lobenhoffer P, RJ van Heerwaarden, AE Staubli, RP Jakob (Eds). Osteotomies around the knee. Georg Thieme Verlag Stuttgart. New York. 2008.
- ² Freiling D, RJ Van Heerwaarden, AE Staubli, P Lobenhoffer (2010). Die varisierende Closed-wedge-Osteotomie am distalen Femur zur Behandlung der unikompartimentalen lateralen Arthrose am Kniegelenk. Oper Orthop Traumatol, 3.
- ³ Van Heerwaarden RJ, A Wymenga. Die suprakondyläre varisierende Femurosteotomie mit speziellem Plattenfixateur. In: Lobenhoffer P, Agneskirchner JD, Galla M (ed.). Kniegelenknahe Osteotomien mit Plattenfixateuren – Indikation, Planung und Operationstechnik. Stuttgart, Thieme Verlag 2006.
- ⁴ Van Heerwaarden RJ, A Wymenga, D Freiling, P Lobenhoffer. Distal medial closed wedge varus femur osteotomy stabilized with TomoFix plate fixator. Operative techniques in Orthopaedics. Vol 17(1) (2007): 12-21.
- ⁵ Van Heerwaarden RJ, JM Brinkman, C Hurschler (2010). Superior axial stability of a new biplane osteotomy technique for Supracondylar Femur Osteotomies fixed with an angular stable plate. Presented at ESSKA 2010.

MRI Information

Torque, Displacement and Image Artifacts according to ASTM F 2213-06, ASTM F 2052-14 and ASTM F 2119-07

Non-clinical testing of worst case scenario in a 3 T MRI system did not reveal any relevant torque or displacement of the construct for an experimentally measured local spatial gradient of the magnetic field of 3.69 T/m. The largest image artifact extended approximately 169 mm from the construct when scanned using the Gradient Echo (GE). Testing was conducted on a 3 T MRI system.

Radio-Frequency-(RF-)induced heating according to ASTM F 2182-11a

Non-clinical electromagnetic and thermal testing of worst case scenario lead to peak temperature rise of 9.5 °C with an average temperature rise of 6.6 °C (1.5 T) and a peak temperature rise of 5.9 °C (3 T) under MRI Conditions using RF Coils (whole body averaged specific absorption rate [SAR] of 2 W/kg for 6 minutes [1.5 T] and for 15 minutes [3 T]).

Precautions: The above mentioned test relies on non-clinical testing. The actual temperature rise in the patient will depend on a variety of factors beyond the SAR and time of RF application. Thus, it is recommended to pay particular attention to the following points:

- It is recommended to thoroughly monitor patients undergoing MR scanning for perceived temperature and/or pain sensations.
- Patients with impaired thermoregulation or temperature sensation should be excluded from MR scanning procedures.
- Generally, it is recommended to use a MR system with low field strength in the presence of conductive implants. The employed specific absorption rate (SAR) should be reduced as far as possible.
- Using the ventilation system may further contribute to reduce temperature increase in the body.

